

# DELAYED SINGLE KIRSCHNER WIRE COMPRESSION TECHNIQUE FOR MALLET FRACTURE

D. FRITZ\*, M. LUTZ, R. ARORA, M. GABL, M. WAMBACHER and S. PECHLANER

*From the Department of Trauma Surgery and Sports Medicine, Innsbruck Medical University, Austria*

**Twenty-four mallet fractures which involved at least one third % of the articular surface of the distal interphalangeal joint were treated by open reduction and internal fixation using a single double-ended Kirschner wire at a mean of 9 days after injury (range 4–15). At a mean follow-up of 43 (range 12–18) months the active range of motion, pain and the Warren and Norris criteria were evaluated. The mean active range of motion was from  $-2^{\circ}$  extension (range  $0-10^{\circ}$ ) to  $72^{\circ}$  flexion (range  $50-90^{\circ}$ ). Nineteen patients were pain free and five suffered from mild pain during strenuous work. The Warren and Norris results were successful in 22 and improved in two cases. Radiographs showed, that all the fractures united in a near-anatomic position but with joint narrowing in six digits.**

*Journal of Hand Surgery (British and European Volume, 2005) 30B: 2: 180–184*

**Keywords:** mallet fracture, subluxation or dislocation of the distal interphalangeal joint, open reduction, anatomic fixation, single Kirschner wire technique

## INTRODUCTION

Mallet finger deformity is caused either by a hyperflexion injury or axial loading of the finger. Mallet finger fractures with a dorsal fragment consisting of more than 30% of the articular surface of the distal interphalangeal joint are unstable and may result in subluxation or dislocation of the distal interphalangeal joint: operative treatment is recommended (Stark et al., 1987).

As the extensor tendon excursion at the distal interphalangeal joint is only 3 mm, healing of the bony fragment with displacement can cause an extension lag and a swan neck deformity (Schmidt and Lanz, 1985; Wehbe and Schneider, 1984).

Several open and closed fixation techniques using pin fixation, extension blocks or wires have been described (Bischoff et al., 1994; Damron and Engber, 1994; Darder-Prats et al., 1998; Hamas et al., 1978; Hofmeister et al., 2003; Ishiguro, 1988; Pegoli et al., 2003; Stark et al., 1987; Takami et al., 2000; Tetik and Gudemez, 2002). Complications following operative treatment include recurrence of deformity, fragmentation of the fracture, infection at the pin site, nail deformity and skin necrosis (Damron and Engber, 1994; King et al., 2001).

A single Kirschner wire technique has been developed which enables anatomic fixation of the fragment and stabilization of the distal interphalangeal joint (Pechlaner et al., 2000).

## PATIENTS AND METHODS

Twenty-four mallet fractures, subtype Wehbe and Schneider 1B, 2B, 3B, were treated by open reduction and internal fixation using a single double-ended Kirschner wire (Table 1) (Wehbe and Schneider, 1984). These fractures occurred in three women and 21 men

with a mean age of 31 (range 15–53) years. The mean time from injury to surgery was 9 (range 4–15) days and the mean follow-up was 43 (range 12–18) months. The little finger was involved in 10 cases, the ring finger in eight, the middle finger in five and the index finger in one case. Thirteen injuries occurred during sporting activities, the other 11 fractures happened at home or as a result of a fall.

## Surgical procedure

A stepwise skin incision is performed dorsally, directly over the fracture of the distal phalanx. After flexion of the distal interphalangeal joint, the fracture site is cleaned of debris and early callus to enable an anatomical reduction. A 1 mm diameter double-ended Kirschner wire is inserted from the fracture site to the fingertip, taking care not to injure the nail bed or the tactile zone of the pulp. The Kirschner wire is withdrawn distally until its end disappears at the fracture site. The distal interphalangeal joint is then extended, the dorsal fracture fragment is reduced, and the Kirschner wire is advanced proximally to fix the fracture fragment and the distal interphalangeal joint in one step (Fig 1).

A finger splint, which stabilizes the distal interphalangeal joint is worn for 4 weeks. The Kirschner wire and the splint are then removed and active range of motion exercises are started.

## Assessment

Pain was assessed subjectively at follow-up on a scale from 1 to 4 (1 – no pain; 2 – mild pain occasionally or with strenuous work; 3 – moderate pain with daily activities which restricts employment; 4 – severe pain

**Table 1—Classification of mallet fractures (Wehbe and Schneider, 1984)**

Classification	Number
Type 1 (no joint subluxation)	
Subtype A	0
Subtype B	14
Subtype C	0
Type 2 (subluxation of the distal interphalangeal joint)	
Subtype A	0
Subtype B	8
Subtype C	0
Type 3 (physis of the distal phalanx involved)	
Subtype A	0
Subtype B	3
Subtype C	0
Total	25

Subtype A: fracture fragment includes < one-third of the articular surface. Subtype B: fracture fragment includes one-third to two thirds of the articular surface. Subtype C: fracture fragment includes > two-thirds of the articular surface.

causing inability to work). Patient satisfaction with the procedure was also assessed (completely satisfied, partly satisfied, dissatisfied). Objective evaluation included measurement of the active range of motion of the distal interphalangeal joint, the clinical appearance of any dorsal deformity at the distal interphalangeal level, nail deformity and skin necrosis. The overall functional outcome was determined with the Warren and Norris criteria (Warren et al., 1988). (Table 2). Radiographs of the distal interphalangeal joint were performed after surgery and at follow-up. These were used to assess bony healing (trabecular bridging), fracture displacement (intra-articular step) and degenerative arthritis (joint space narrowing – grade 1; spur formation – grade 2; absent joint space – grade 3).

**RESULTS**

Nineteen patients were pain free and the other five only experienced mild pain during strenuous work. All patients were satisfied with their level of function and cosmetic result. The average loss of active extension of the distal interphalangeal joint was 2° (range 0–10°). Twenty-one fingers had full distal interphalangeal extension, whereas three fingers had an extension lag of up to 10°. The mean flexion of the distal interphalangeal joint was 72° (range 50–90°).

None of the digits had a significant dorsal bump or any residual mallet deformity. Minimal ridging of the nail occurred in two patients, but pin tract infections, migration and skin necrosis were not encountered. There were 22 successful and two improved results according to the Warren and Norris evaluation criteria (1988).

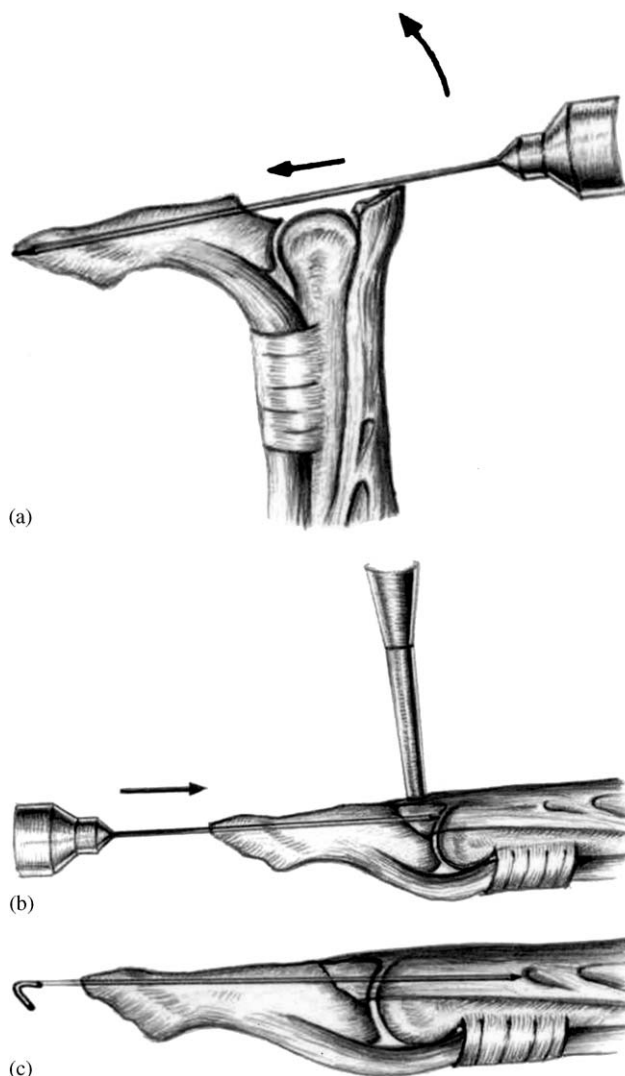


Fig 1 (a) A 1 mm double-ended Kirschner wire is driven from the fracture site into the fingertip. (b) The distal interphalangeal joint is extended and the avulsed fragment is reduced. The Kirschner wire is then driven proximally. (c) The distal interphalangeal joint is fixed in extension by driving the Kirschner wire into the middle phalanx.

**Table 2—Warren and Norris classification (1988)**

Classification	Extension Loss
Success	0° to 5°
Improved	6° to 15°
Failure	> 15°

Radiographs obtained at follow-up showed bone union in all cases. Slight degenerative changes occurred in six digits (grade-one arthritis). An intra-articular step

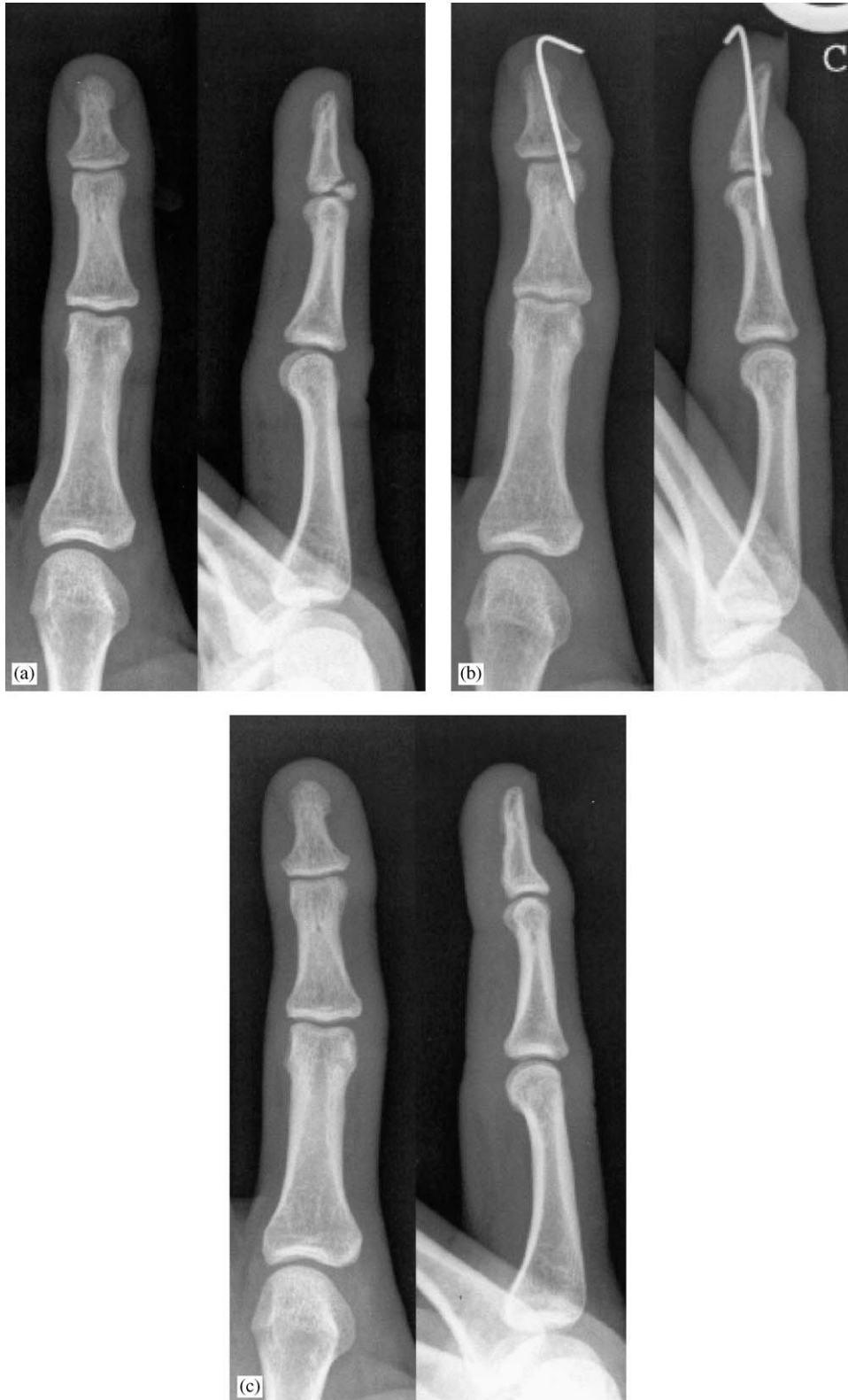

Fig 2 (a) A 22-year - old man with a mallet fracture involving more than 30% of the base of the distal phalanx. (b) Anatomic reduction, fixation of the avulsed fragment and transfixation of the distal interphalangeal joint by a single Kirschner wire. (c) At follow-up the fracture had healed in an anatomical alignment and there were no degenerative changes.

off of less than 1 mm was present in four joints (Fig 2).

## DISCUSSION

The treatment of mallet finger fractures is determined by the size of the articular fragment. Small bony avulsions can be treated conservatively in a splint (Brzeziński and Schneider, 1995; Niechajev, 1985; Stark et al., 1962) but splintage of fragments which consist of more than 30% of the articular surface in the lateral projection may result in an extension lag of the distal interphalangeal joint due to displacement (Wehbe and Schneider, 1984). As a result, operative treatment is now favoured by many for this fracture size. Open reduction and internal fixation with two or more Kirschner wires produced good results with an extension lag of 2 to 5° (Hamas et al., 1978; Stark et al., 1987; Takami et al., 2000). An extension lag of 4° to 30° with a 70° average range of flexion was observed following wire fixation of the distal interphalangeal joint in combination with pull out wire fixation of the fracture fragment (Damron and Engber, 1994; King et al., 2001). Tension band wiring of mallet fractures has resulted in an average range of motion at the distal interphalangeal joint of 50° (Bischoff et al., 1994). The extension block Kirschner wire technique allows closed reduction of the fragment with transfixation of the distal interphalangeal joint but may result in extension lags of up to 20° and a complication rate of 5% to 60% (Darder-Prats et al., 1998; Hofmeister et al., 2003; Pegoli et al., 2003; Tetik and Gudemez, 2002). Complications experienced included pin tract infections, nail deformities, skin necrosis, spur formation, joint narrowing and loss of the fracture reduction. Good results without any complications were reported by Ishiguro who treated 10 patients by the closed reduction and extension block technique, with a mean follow-up of 3½ months (Ishiguro, 1988).

Our single Kirschner wire technique enabled fixation of the fragment as well as transfixation of the distal interphalangeal joint in one step, thus avoiding multiple attempts at pinning which may occur with closed techniques.

As the reduction of the fragment is maintained by the pin, additional fracture fixation which could cause damage to the soft tissues and the nail bed is avoided. Complications such as dorsal and palmar skin necrosis, finger pulp infection, major nail deformity and implant and bone prominence were not observed in our series.

The extension lags observed in our series were similar to those after other open techniques and some closed techniques (Darder-Prats et al., 1998; Ishiguro, 1988; Tetik and Gudemez, 2000). Only slightly decreased flexion at the distal interphalangeal joint level was observed in our series or in other studies (Damron et al.,

1998; Stark et al., 1987; Takami et al., 2000). Scar formation which restricts gliding of the extensor tendon is probably the cause of this.

Osteoarthritis has been reported following open reduction, whereas degenerative changes have not been assessed in series reporting the results of closed reduction and percutaneous pinning. Anatomic reduction and fixation is not easily achieved by a closed surgical techniques if surgery is delayed, and residual articular incongruity and heat necrosis of bone and cartilage due to multiple attempts at Kirschner wire placement may lead to degenerative arthritis in the long term (Khanna et al., 1999). Our procedure provides good radiological and clinical results, especially if the patient presents after a delay and callus formation has already commenced. It should prevent the development of degenerative arthritis.

## REFERENCES

- Bischoff R, Buechler U, Roche RD, Jupiter J (1994). Clinical results of tension band fixation of avulsion fractures of the hand. *Journal of Hand Surgery*, 19A: 1019–1026.
- Brzeziński MA, Schneider LH (1995). Extensor tendon injuries at the distal interphalangeal joint. *Hand Clinics*, 11: 373–386.
- Damron TA, Engber WD (1994). Surgical treatment of mallet finger fractures by tension band technique. *Clinical Orthopaedics and Related Research*, 300: 133–140.
- Darder-Prats A, Fernandez-Garcia E et al. (1998). Treatment of mallet finger fractures by the extension-block k-wire technique. *Journal of hand surgery*, 23B: 802–805.
- Hamas RS, Horrell ED, Pierret GP (1978). Treatment of mallet finger due to intra-articular fracture of the distal phalanx. *Journal of Hand Surgery*, 3A: 361–363.
- Hofmeister EP, Mazurek MT, Shin AY, Bishop AT (2003). Extension block pinning for large mallet fractures. *Journal of Hand Surgery*, 28A: 453–459.
- Ishiguro T (1988). A new method of closed reduction for mallet fractures. *Central Japanese Journal of Orthopaedic and Trauma Surgery*, 31: 2049–2051.
- Khanna A, Plessas SJ, Barrett P, Bainbridge LC (1999). The terminal effects of Kirschner wire fixation on small bones. *Journal of Hand Surgery*, 24B: 355–357.
- King HJ, Shin SJ, Kang ES (2001). Complications of operative treatment for mallet fractures of the distal phalanx. *Journal of Hand Surgery*, 26B: 28–31.
- Niechajev IA (1985). Conservative and operative treatment of mallet finger. *Plastic and Reconstructive Surgery*, 76: 580–585.
- Pegoli L et al. (2003). The Ishiguro extension block technique for the treatment of mallet finger fracture: indications and clinical results. *Journal of Hand Surgery*, 28B: 15–17.
- Pechlaner et al. (2000). *Atlas of hand surgery*. New York: Thieme Stuttgart.
- Schmidt HM, Lanz U (1985). Die Gleitamplitude von Beuge- und Strecksehnen der Finger an der menschlichen Hand. *Handchirurgie, Mikrochirurgie, Plastische Chirurgie*, 17: 307–313.
- Stark HH, Boyes JH et al. (1962). Mallet finger. *Journal of Bone and Joint Surgery*, 44A: 1061–1068.
- Stark HH, Gainor BJ, Ashworth CR, Zemel NP, Rickard TA (1987). Operative treatment of intra-articular fractures of the dorsal aspect of the distal phalanx of digits. *Journal of Bone and Joint Surgery*, 69A: 892–896.
- Takami HI, Takahashi SA, Ando MA (2000). Operative treatment of mallet finger due to intra-articular fracture of the distal

- phalanx. Archives of Orthopaedic and Trauma Surgery, 120: 9–13.
- Tetik CI, Gudemez EF (2002). Modification of the extension block Kirschner wire technique for mallet fractures. Clinical Orthopaedics and Related Research, 404: 284–290.
- Warren RA, Norris SH, Ferguson DG (1988). Mallet finger: a trial of two splints. Journal of Hand Surgery, 13B (2): 151–153.
- Wehbé MA, Schneider LH (1984). Mallet fractures. Journal of Bone and Joint Surgery, 66A: 658–669.

---

Received: 16 January 2004

Accepted after revision: 12 October 2004

\*Dr Dagmar Fritz, Department of Trauma Surgery and Sports Medicine, Medical University, Anichstr.35, 6020 Innsbruck, Austria.. Tel.: +43 512 504 22821; fax: +43 512 504 22824  
E-mail: dagmar.fritz@uibk.ac.at

© 2005 The British Society for Surgery of the Hand. Published by Elsevier Ltd. All rights reserved.

doi:10.1016/j.jhsb.2004.10.012 available online at <http://www.sciencedirect.com>