

INJURIES TO THE HAND FROM DOG BITES

I. GRANT and H. J. C. R. BELCHER

From the Department of Plastic Surgery, Queen Victoria Hospital, East Grinstead, UK

A review of dog bite injuries referred to one surgeon over a 12 month period demonstrated a significant association between a delay in referral and a prolonged period of subsequent in-patient treatment. Two patients sustained injuries when delivering material through a letter-box.

Journal of Hand Surgery (British and European Volume, 2000) 25B: 1: 26–28

Dog bites are a common cause of injury and account for one in 200 accident and emergency department attendances (Sacks et al., 1996). Most of these injuries can be managed with oral antibiotics and out-patient treatment (Maimaris and Quinton, 1988; Moore, 1997). Although many victims regard their injuries as trivial, a small number of untreated patients may go on to develop overwhelming systemic infection (Mellor et al., 1997).

Approximately 20% of dog bites involve the hand (Dire et al., 1994). These injuries are more likely to become infected than are bites to the arm, leg, or face (Wiggins et al., 1994). Inappropriate initial management of dog bites to the hand is thought to predispose to prolonged treatment and protracted morbidity. A retrospective review of all such patients referred to one hand surgeon over a 12 month period has been conducted. It was our intention to characterize patterns of injury, and to identify patient groups associated with a poorer outcome after injury.

METHODS

We reviewed the records of all patients who had sustained dog bites to the hand who were referred to one surgeon over a 12 month period (March 1998–March 1999). All had undergone initial assessment and management of the injuries within the first 24 hours after the dog bite at a local primary care centre by accident and emergency physicians or by nurse-practitioners. Tetanus immunization was undertaken if indicated. All initial surgical procedures were performed within 24 hours of admission to the specialist hand-centre. In each case the wounds were explored under regional or general anaesthesia. Thorough wound debridement and irrigation were carried out. Disrupted structures including bones, tendons, nerves and blood vessels were repaired at the time of the initial surgical procedure unless such measures were contra-indicated by overwhelming tissue destruction or contamination.

The results from this study are presented as mean and standard deviation (SD) values. Median values are given for non-normally distributed data. Correlation was assessed using the Pearson product moment test using two-tailed analysis.

RESULTS

During the study period 24 patients were referred for treatment. All required inpatient treatment. Their ages ranged from 4 to 82 years with a mean of 48 (19.5) years. There were 12 female and 12 male patients. When patients were referred on the same day as the initial assessment of the injury, a delay of 0 days was recorded. The delay between the initial assessment at the primary care hospital and subsequent referral to our centre ranged from 0 to 14 days, with a median of 1 day. Fifteen of the 24 patients requiring in-patient treatment were referred within less than 2 days of their initial assessment.

The length of in-patient treatment at our centre ranged from 1 to 14 days with a median of 2 days. Nine patients required only 1 day of in-patient treatment. No difference was detected between the length of in-patient treatment for either male or female patients or for patients older or younger than 50 years. However, a delay in referral was associated with a longer period of in-patient treatment. (Fig 1).

All patients were given intravenous antibiotics. Agents used were either co-amoxiclav (14 of 24 patients) or a combination of agents able to achieve cover against the most likely infecting organisms – *Pasteurella multocida*, streptococcal species, anaerobes and *Staphylococcus aureus* (Moore, 1997). All but one of the patients required surgery. Only two required more than one operation. In nine, local flaps or full thickness skin-grafts were required to achieve wound closure. In two, the injured digit was terminalized at the level of the distal phalangeal joint (DIPJ). In both instances the mechanism of injury was similar, as described in the case histories below.

The breed of dog responsible for the injury was determinable from referral to medical records and by direct inquiry in 21 patients. Only one breed was clearly identified in more than two instances. An Alsatian (German Shepherd) was responsible for the injuries sustained by four patients.

Four identifiable mechanisms of injury were identified. Attempting to pick up an object wanted by the dog such as a ball or stick (five patients), stroking or patting a dog (three patients), separating two or more dogs (five patients), and bites to the hand whilst pushing letters or pamphlets through a letter box (two patients). The

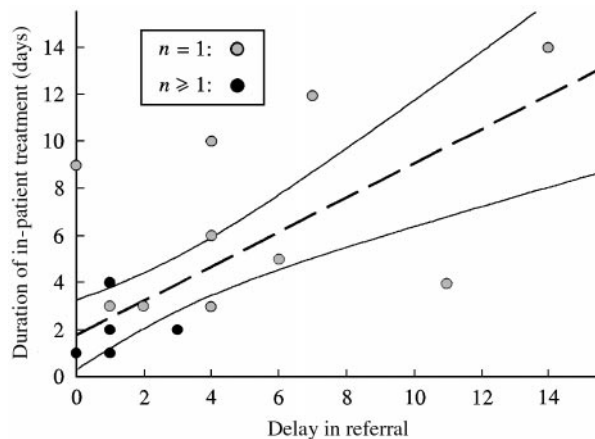


Fig 1 The scattergram represents the relationship between the delay in referral and the subsequent period of in-patient hospital treatment. Confidence intervals of 95% are shown. Pearson product moment correlation $r^2=0.475$ indicating a significant relationship ($P=0.0002$).

pattern of injury sustained whilst delivering letters is described below.

CASE HISTORIES

Case 1

A 34-year-old female traffic warden was pushing a leaflet through the waist-height letterbox of a neighbour's front door. Without warning, she was bitten on the ring finger of the right hand by a Staffordshire bull terrier. She could not initially extract the finger, which was for

several seconds clamped within the dog's mouth. Immediately after the injury, she reported to the local accident and emergency centre. She was prescribed oral co-amoxiclav (250/125 mg) and was asked to return for further assessment the next day. It was at this point noted that there was a mallet finger deformity of the distal phalanx associated with a fracture of the middle phalanx at the level of the DIPJ. She was referred to our centre for further treatment. The initial appearance of her injury was relatively innocuous and is shown in Figure 2. However, on exploration, there was a gross disruption of the DIPJ with loss of most of the articular surface. Both the extensor and flexor tendons were divided. There was a segmental loss of the radial neurovascular bundle. After consultation with the patient, the digit was terminalized immediately proximal to the DIPJ.

Case 2

A 52-year-old male care worker was pushing a large pamphlet through the waist-height letterbox of a wooden front door, when a Border collie bit and firmly gripped the distal phalanx of the middle finger of his dominant hand. He could not release the finger, which was held by the dog on the other side of the door. When he finally extracted the hand, the entire distal phalanx had been torn away by the dog. The amputated portion of his finger could not be retrieved. He reported to the local accident and emergency centre and was referred to our centre on the same day. He had sustained a traumatic amputation of the digit immediately distal to the DIPJ (Fig 3). After thorough debridement and

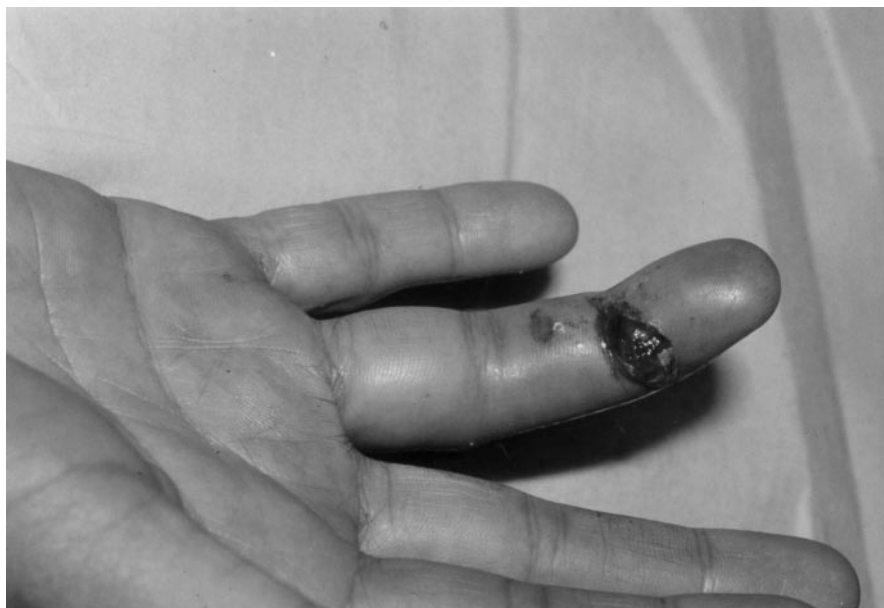

Fig 2 Case 1. A deep laceration can be seen along the radial border of finger at the level of the DIPJ.

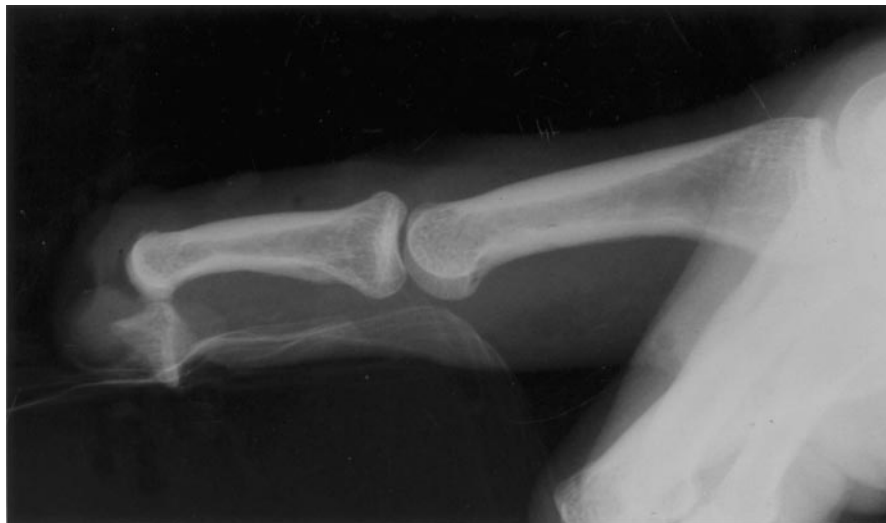

Fig 3 Case 2. The radiological appearance of the injured digit. The distal phalanx was traumatically amputated immediately distal to the DIPJ.

irrigation under regional anaesthesia the finger was terminalized immediately proximal to the DIPJ.

DISCUSSION

In this study, restricted to dog bite injuries to the hand, the mean age of patients was 48 years. In another study, the mean age of patients presenting to a primary care centre with dog bite injuries was 13 years (Dire et al., 1994). Children commonly sustain dog bites to the head and neck, rather than to their hands (Chait and Spitz, 1975).

The only one breed of dog involved in more than two instances in the present study was the Alsatian. This observation is consistent with a previous report that identified this breed as a frequent cause of dog bite injury in children (Chait and Spitz, 1975). In no instance was there a history of dogs attacking in packs, which has been reported as a rare but severe cause of injury (Kneafsey and Condon, 1995). The circumstances of dog bites identified by Shewell and Nancarrow (1991) were: victim "invading" the dog's territory; victim seen as a threat to the dog's "family"; victim seen as a threat to the dog; and a jealous dog. To these we would add: victim taking something wanted by the dog.

The highly significant relationship between a delay in referral to a specialist hand surgery centre and prolonged subsequent treatment confirms the importance of proper initial assessment and management of hand injuries. Case 1 exemplifies the discrepancy between the real and the apparent severity of these injuries as well as their potential impact. The recognition of the severity of these injuries and the earlier referral of patients might avoid morbidity and the use of resources associated with prolonged in-patient treatment.

The two case histories illustrate a pattern of injury associated with a particular activity. It is interesting that neither patient was a postal worker. A number of factors, including the expansion of direct postal marketing and the growth in number of local newspapers, have caused an increase in the frequency with which material is pushed through each household's front door. Many of these deliveries are made by casual workers who perhaps might not be as wary as postal officers.

References

- Chait LA, Spitz L (1975). Dogbite injuries in children. *South African Medical Journal*, 49: 718–720.
- Dire DJ, Hogan DE, Riggs MW (1994). A prospective evaluation of risk factors for infections from dog-bite wounds. *Academic Emergency Medicine*, 1: 258–266.
- Kneafsey B, Condon KC (1995). Severe dog-bite injuries, introducing the concept of pack attack: a literature review and seven case reports. *Injury*, 26: 37–41.
- Maimaris C, Quinton DN (1988). Dog-bite lacerations: a controlled trial of primary wound closure. *Archives of Emergency Medicine*, 5: 156–161.
- Mellor DJ, Bhandari S, Kerr K, Bodenham AR (1997). Man's best friend: life threatening sepsis after minor dog bite. *British Medical Journal*, 314: 129–130.
- Moore F (1997). I've just been bitten by a dog. *British Medical Journal*, 314: 88–90.
- Sacks JJ, Kresnow M, Houston B (1996). Dog bites: how big a problem? *Injury Prevention*, 2: 52–54.
- Shewell PC, Nancarrow JD (1991). Dogs that bite. *British Medical Journal*, 303: 1512–1513.
- Wiggins ME, Akelman E, Weiss AP (1994). The management of dog bites and dog bite infections to the hand. *Orthopedics*, 17: 617–623.

Received: 30 June 1999

Accepted after revision: 13 September 1999

H. J. C. R. Belcher FRCS(Plast), Department of Plastic Surgery, Queen Victoria Hospital NHS Trust, Holtye Road, East Grinstead, West Sussex RH19 3DZ, UK.

© 2000 The British Society for Surgery of the Hand

DOI: 10.1054/jhsb.1999.0320, available online at <http://www.idealibrary.com> on IDEAL®